

Root Canal Morphology of Mandibular First Permanent Molars in Pakistani Sub-population – An in vitro study

USMAN SANA¹, IFFAT UMAIR NIAZI², RAMLA SAHIB DIN³, MUBASHIR RASHEED⁴, IRSAM HAIDER⁵, OMER YOUSAF⁶

¹Assistant Professor / HOD Operative Dentistry Department, Islam Dental College, Sialkot

²Senior Registrar Operative Dentistry, Islam Dental College Sialkot.

³Dental Cosmetics and Implant Centre, Johar Town, Lahore.

⁴Assistant Professor, Department of Operative Dentistry, College of dentistry, Sharif Medical and Dental College, Lahore.

⁵Assistant Professor/ Head, Department of Paedodontics, College of dentistry, Sharif Medical and dental college, Lahore.

⁶Professor, Lahore Medical & Dental College, Lahore.

Correspondence to Omer Yousaf, Email: omer.yousaf@lmdc.edu.pk, Cell: 0300-9448018

ABSTRACT

Aim : To investigate the number and patterns of root canals of mandibular first molars.

Methods: Descriptive observational study to investigate the canal morphology using clearing technique. The duration of the study was one year from 1st February 2020 to 1st February 2021. Non purposive sampling technique was used and 200 mandibular first molar were collected. Data collected was analysed using the SPSS Vr 10. Study variables include Number and pattern of the roots in mandibular teeth. Descriptive statistics were used; frequencies of the root canals and their canal pattern were calculated.

Results: In the mesial root, 14 teeth had a one root canal, 186 possessed double root canals were observed. Distal root of 160 teeth possessed one canal, 40 teeth possessed two root canals with type 1 pattern mostly observed.

Conclusion: Like other populations Pakistani population may have a diverse root canal system in the mandibular molars that ultimately affect endodontic therapy.

Keywords: Roots, canals, anatomy, tooth clearing technique, demineralization

INTRODUCTION

Dental pulp is involved in endodontics, so all aspects of root canal anatomy must be taken into account before commencing the endodontic therapy¹. Variability in anatomical features like pattern and number of canals, inter canal connections, accessory canals, multiple foramina, C-shaped canals, apical isthmuses². For a predictable endodontic outcome it is therefore mandatory to have knowledge of the root canal system¹⁻⁴.

The variation in the root canal anatomy can affect the endodontic treatment outcome. Maxillary first molars have been identified possessing two palatal canals within a one root⁵. Presence of isthmuses in the molars also affects outcome of the endodontic therapy⁶. Mandibular second molars with anatomical variance pose problems in the endodontic therapy^{7,8,9}. Single rooted maxillary molar with a single canal has also been reported¹⁰.

Numerous techniques are used to determine the variation in the root canal anatomy. Radiographs form the basic and important tool in endodontic practice. Three dimensional digital imaging augments accurate reconstruction of the canal anatomy^{11,12,14}. Stereomicroscopy and micro-computerized tomography have been advocated to reconstruct canal anatomy in teeth¹⁵. Tooth clearing and demineralization are also use to study canal anatomy¹⁶.

Deviation in root anatomy is a common finding in mandibular molars¹⁷⁻¹⁸. Over 50% of the maxillary first molars of the Thai population had a second mesiobuccal canal¹⁹⁻²⁰. Similar variations were also reported in studies done on Burmese and Ugandan population²²⁻²³.The

lengths of the teeth were shorter in Asian when compared with the Caucasians²⁴.

The study was designed discover the number and pattern of canals in permanent mandibular molars.

PATIENTS AND METHODS

The study was descriptive observational by design. Carried out in The Department of Operative Dentistry, Islam Dental College, Sialkot, Pakistan. The duration of the study was one year from 1st February 2020 to 1st February 2021. Non purposive sampling technique was used to collect 200 mandibular first molar teeth. Extracted teeth were removed without the roots being fractured and with sufficient crown morphology present to aid identification of the tooth were included. Teeth with fractured roots, root treated teeth, with too little crown structure that may alter tooth identification, teeth collected from patients that were diagnosed with disorders possibly involving tooth structure (Ectodermal dysplasia, Cleidocranial dysplasia, Enamel hypoplasia, Amelogenesis imperfecta, Dentinogenesis imperfecta etc.) and teeth with extensive caries involving the roots were excluded. This study was approved by Ethical Review Board of LMDC.

Teeth were washed after extraction. They were stored thymol iodide crystals solution. Once 200 teeth were collected, they were immersed in sodium hypochlorite (2.5%) for half an hour. This will help remove the soft tissues. Ultrasonic instruments were used for removal of calculus and stains on teeth. Access cavity was done in each tooth. Endodontic explorer was used for the identification of canals. Immersing teeth for 48 hours in 0.5% sodium hypochlorite helps dissolve the pulpal tissue. Teeth were kept in separate glass test tubes containing

Received on 24-02-2021

Accepted on 23-05-2021

nitric acid (5%). Indian ink was injected in canals with the help of 27 gauge needle. High power suction was placed apically during the injection of the ink. Teeth were immersed in methyl salicylate for 2 hours. After a period of two hour the teeth became transparent. The magnifying glass used for the observation of the root canals had 3x magnifications. Root canals were classified using Vertucci classification. Data collected was analysed using SPSS.

RESULTS

Two hundred permanent mandibular molars were included. There were no drop outs and all 200 teeth were included in the final calculation. All the teeth included had two roots; mesial and distal, single canal found in 14 teeth, two canals found in 186 teeth, single canal found in distal root of 160 teeth, two canals found in distal root of 40 teeth. In the mesial roots Type I, Type III and type VIII pattern was not seen in any teeth, Type II and Type VII in 3 tooth each, Type IV in 108 teeth, Type V in 82 teeth and Type VI in 5 teeth. In distal roots Type I pattern was found in 162 teeth, Type II pattern in 5 teeth, Type IV pattern in 13 teeth, Type V pattern was seen in distal roots of 20 teeth.

Table 1: Mandibular molars: Number of Canals

Pattern of root canal	Mesial Root	Distal root
Single	14	160
Double	186	40
Total	200	200

Table 2: Mandibular molars; Pattern of Canals

Pattern of root canal	Mesial Root	Distal root
Type-I	0	162
Type-II	3	5
Type-III	0	0
Type-IV	108	13
Type-V	82	20
Type-VI	5	0
Type-VII	3	0
Type-VIII	0	0
Total	200	200

Fig 1: Percent of male and females included in the study

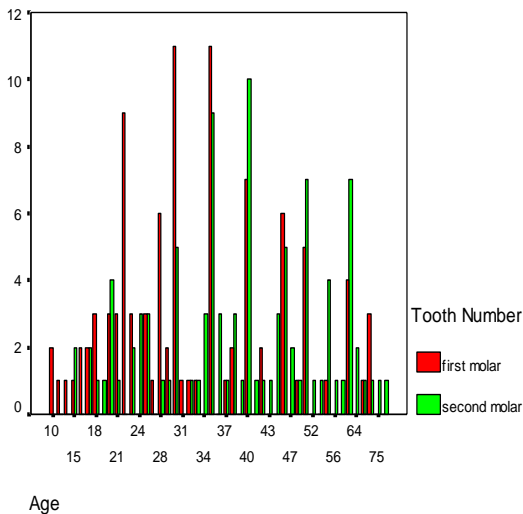
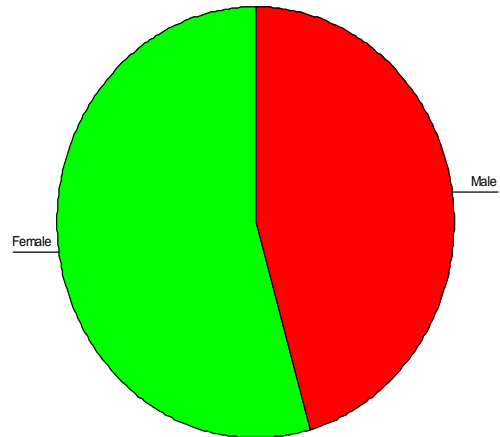


Fig 2 : Gender distribution in sample size



DISCUSSION

For successful endodontics, identify, clean, shape and obturate the canals. The goal can only be achieved if there is complete understanding of the canals anatomy. Racial difference in morphology is an important factor to be considered. Studies conducted on the anatomy pointed out that variation exist among different populations¹⁹⁻²⁴.

Employed techniques include the radiological technique, root sectioning technique and clearing techniques¹²⁻¹⁵. The tooth clearing technique has been advocated to be more reliable one¹⁴. It is the least invasive in regard of altering the root morphology during the process of tooth clearing. Radiological technique has the limitation of being a two dimensional view of a three dimensional object¹⁰. Human handling error in the process of root sectioning and destruction of the tooth structure may alter the actual anatomical landmark¹³. Great details are obtained using the clearing technique²⁵. Adequate ink penetration is necessary for examination of the fine details.

Roots were classified using Vertucci's classification. 186(93%) teeth in mesial root possessed two root canals, whereas 14(7%) teeth in mesial root possessed one root canal. Type IV pattern was observed in 108(54%) teeth. Type V pattern was present in 82(41%) teeth. Type VI pattern presented in 5(2.5%) teeth. Type II pattern presented in 3(1.5%) teeth. 90% of the cases reported in the Burmese population which had two separate roots²³. The Iranian population presented with 98.56% two roots and 1.44% possessed three canals in molars²⁶.

The distal root possessed Type I pattern in 162(81%) teeth. Type IV pattern was observed in 13(6.5%) teeth. Type V pattern was possessed in 20(10%) teeth. Type II pattern possessed in 5(2.5%) teeth. In Sudanese population 59% first molars possessed four canals²¹. The Iranian population presented with 98.56% two roots and 1.44% had three roots in the first mandibular molars²⁶. 31.57% had four root canals and 2.87% had two canals.

Mean age of patients with Type II canals was 32.00 years, with Type III canals was 39.00 years, with Type IV canals was 35.35 years, with Type V canals was 39.15, with Type VI canals was 34.50 years and with Type VII canals was 27.50 years. Van der sluis, Wu and Wesselink²²

mentioned the changes in the root canal dimensions with age. They observed that by the age of 40 years canal size decreases to an oval shape of less than 2mm dimension. Studies conducted at a larger scale may help us improve our endodontic treatment outcome.

CONCLUSION

Like other populations Pakistani population may have a variety of canal configuration in mandibular first molar that ultimately affects outcome of the endodontic treatment. Canal anatomy knowledge helps improve the standard of endodontic care provided to the patients. This study conducted in the Islam Dental College represented a small sample of the Pakistani sub-population.

Conflict of interest: None

REFERENCES

- Ahmed HMA, Versiani MA, De-Deus G, Dummer PMH. A new system for classifying root and root canal morphology. *Int Endod J.* 2017 Aug;50:761-770.
- Vertucci FJ. Root canal morphology and its relationship to endodontic procedures. *Endodontic topics* 2005;10:3-29.
- Alfawaz H, Alqedairi A, Al-Dahman YH, Al-Jebaly AS, Alnassar FA, Alsubait S, Allahem Z. Evaluation of root canal morphology of mandibular premolars in a Saudi population using cone beam computed tomography: A retrospective study. *Saudi Dent J.* 2019 Jan;31:137-142.
- Siqueira Junior JF, Rôças IDN, Marceliano-Alves MF, Pérez AR, Ricucci D. Unprepared root canal surface areas: causes, clinical implications, and therapeutic strategies. *Braz Oral Res.* 2018 Oct 18;32:e65
- Shemesh A, Kavalerchik E, Levin A, Ben Itzhak J, Levinson O, Lvovsky A, Solomonov M. Root Canal Morphology Evaluation of Central and Lateral Mandibular Incisors Using Cone-beam Computed Tomography in an Israeli Population. *J Endod.* 2018 Jan;44:51-55
- Demiriz L, Bodrumlu EH, Icen M. Evaluation of root canal morphology of human primary mandibular second molars by using cone beam computed tomography. *Niger J Clin Pract.* 2018 Apr;21(4):462-467.
- Seo MS, Park DS. C-shaped root canals of mandibular second molars in Korean population: clinical observation and in vitro analysis. *Int Endod J.* 2004;37:139-144.
- Holtzmann L. Root canal treatment of a mandibular first molar with three mesial root canals. *Int Endod J.* 1997;30:422-423.
- Torre FDL. Single-rooted maxillary first molar with a single canal: endodontic treatment. *Oral Surg Oral Med Oral Pathol.* 2008;32:622-623
- Krithika AC, Kandaswamy D, Velmurugan N, Krishna VG. Non-metallic grid for radiographic measurement. *Aus Endod J.* 2007;34:36-38.
- Dong J. Theories and algorithms for 3-D root canal model construction. *Computer-Aided Design.* 2005;37:1177-1189.
- Mannocci F, Peru M, Sherriff M, Cook R, Pitt Ford TR. The isthmus of the mesial root of mandibular molars: a micro-computed tomographic study. *Int Endod J.* 2005;38:558-563.
- Nekoofar MH, Ghandi MM, Hayes SJ, Dummer PMH. The fundamental operating principles of electronic root canal length measurement devices. *Int Endod J.* 2006;39:595-609.
- Nagy CD, Bartha K, Bernath M, Verdes E, Szabo J. The effect of root canal morphology on canal shape following instrumentation using different techniques. *Int Endod J.* 1997;30:133-140.
- Cheung GSP, Yang J, Fan B. Morphometric study of the apical anatomy of the C-shaped root canal systems in mandibular second molars. *Int Endod J.* 2007;40:239-246.
- Venturi M, Prati C, Capelli G, Falconi M, Breschi L. A preliminary analysis of the morphology of the lateral canals after root canal filling using a tooth clearing technique. *Int Endod J.* 2003;36:54.
- Pattanshetti N, Gaidhane M, AL Kandari M. Root and canal morphology of the mesiobuccal and distal roots of permanent first molars in a Kuwait population – a clinical study. *Int Endod J.* 14th July 2008.
- Awawdeh LA, Al-Qudah AA. Root form and canal morphology of mandibular premolar in a Jordanian population. *Int Endod J.* 2007;41:240-248.
- Alavi AM, Opasanon A, Ng Y-L, Gulabivala K. Root canal morphology of Thai maxillary molars. *Int Endod J.* 2002;35:478-485.
- Alavi AM, Opasanon A, Ng Y-L, Gulabivala K. Root canal morphology of Thai mandibular molars. *Int Endod J.* 2002;35:56-62.
- Ahmed HA, Abu-bakr NH, Yahia NA, Ibrahim YE. Root and canal morphology of permanent mandibular molars in a Sudanese population. *2007;40:766-771.*
- Rwenyonyi CM, Kutesa, Muwazi LM, Buwembo W. Root and canal morphology of maxillary first and second permanent molar teeth in a Ugandan population. *2007;40:679-683.*
- Gulabivala K, Aung TH, Alavi A, Ng Y-L. Root and canal morphology of Burmese mandibular molars. *2001;34:359-370.*
- Kim E, Fallahrastegar A, Hur YY, Jung I-Y, Kim S, Lee S-J. Difference in root canal length between Asians and Caucasians. *2005;38:149-151.*
- Peiris R, Takahashi M, Sasaki K. Root canal morphology of permanent mandibular molars in a Sri Lankan Population. *Odontology.* 2007;95:16-23.
- Shahi S, Yavari HR, Rahimi S. Root canal morphology of human mandibular first permanent molars in an Iranian Population. *JODDD.* 2008;2:1.